

# Photorefractive Keratectomy for Hyperopia Using an Erodible Disc and Axicon Lens: 2-Year Results

Francesco Carones, MD; Rosario Brancato, MD; Alessandro Morico, MD; Luca Vigo, MD; Elisabetta Venturi, MD; Pier Giorgio Gobbi, PhD

## ABSTRACT

**BACKGROUND:** This paper presents the results over a 2-year follow-up of the first human trial of photorefractive keratectomy (PRK) for correction of hyperopia using an erodible disc excimer laser delivery system (Summit) coupled to an axicon lens.

**METHODS:** We treated 25 eyes of 21 patients for a mean correction of  $+3.38 - 0.97$  D (range,  $+1.00$  to  $+4.00$  D). The hyperopic correction was made using an erodible disc inserted on the laser optical pathway; an axicon lens was then used to create a blend transition zone. Eyes were evaluated at 1, 3, 6, and 12 months after surgery. For a smaller series of 11 eyes, we also present 24-month results.

**RESULTS:** Mean refractive error 1 month after treatment (25 eyes) was  $-2.35 - 1.55$  D (range,  $+1.00$  to  $-6.50$  D). Eight eyes (32%) had a spectacle-corrected visual acuity loss greater than 1 line. Twelve months after treatment, mean spherical equivalent refraction was  $-0.47 - 0.80$  D (range,  $+1.25$  to  $-2.25$  D). Nineteen eyes showed an improvement (range, 3 to 8 lines) in uncorrected distance visual acuity and 23 showed improvement in uncorrected vision at reading distance (1 to 7 lines).

**CONCLUSION:** This technique proved effective

in reducing hyperopia, but predictability must be demonstrated in a larger treatment group. Safety was confirmed by the absence of delayed reepithelialization and the absence of spectacle-corrected visual acuity loss greater than 1 line at 1 year after surgery. [*J Refract Surg* 1998;14:504-511]

The argon fluoride 193 nm excimer laser is currently used to correct refractive errors<sup>1</sup> and other visual disturbances.<sup>2,3</sup> Excimer laser photorefractive keratectomy (PRK) has proven effective and predictable in the correction of low to moderate myopia<sup>4-8</sup>, and recent papers report satisfactory results even in the correction of high myopia.<sup>9</sup> Myopic PRK is performed by reshaping of the anterior corneal curvature: a shallow circular and symmetric lenticule, thicker in its center than in its periphery, is ablated to flatten the corneal surface overlying the pupil.<sup>10</sup> The ablation is performed mainly using opening diaphragms or flying-spot scanning delivery systems, allowing greater energy delivery in the central part of the cornea.

The correction of myopia is not the only application of the excimer laser in refractive surgery. Greater flattening can be obtained along one single meridian by performing asymmetrical ablation to correct myopic astigmatism<sup>11-14</sup>, or the central cornea can be steepened by ablation of peripheral corneal tissue to correct hyperopia. This effect can be produced using a variety of energy delivery systems, such as flying-spot scanning ablations, rotating masking agents, peripherally-rotating slit delivery systems, or erodible discs.

The erodible disc delivery system uses a shape transfer process, where the three-dimensional profile of a polymethylmethacrylate (PMMA) lens with the desired dioptric correction is transferred onto the corneal surface by photoablation of the lens itself.<sup>15-18</sup>

---

*From the Department of Ophthalmology and Visual Sciences (Carones, Brancato, Morico, Vigo, Venturi) and the Laser Medicine Research (Gobbi), Scientific Institute San Raffaele Hospital, University of Milan, Italy.*

*Presented in part at the 1996 Annual Meeting of the Association for Research in Vision and Ophthalmology (ARVO) in Fort Lauderdale (Fla, USA) on April 21-26, 1996.*

*The authors have no financial or proprietary interest in the materials described.*

*Correspondence: Prof. Rosario Brancato, Department of Ophthalmology and Visual Sciences, Scientific Institute H S. Raffaele, via Olgettina, 60, 20132 Milano, Italy. Tel: 39-2 2643 3598; Fax: 39-2 2641 2912; Email: brancato.rosario@hsr.it*

*Received: March 9, 1998*

*Accepted: June 23, 1998*

We report the results of the first human trial for hyperopia correction using an excimer laser with the new feature of positioning the erodible disc directly in the laser's optical rail, a considerable distance from the patient's eye. After ablation of the disc, an axicon lens was used to enlarge the ablation diameter and create a blend zone up to 9.4 mm wide.

## PATIENTS AND METHODS

### Patient Assessment

We treated 25 consecutive eyes of 21 patients who all gave informed consent after the experimental nature of the procedure had been explained. The Ethics Committee of the San Raffaele Hospital approved the research protocol. There were 12 men and 9 women, mean age of 46 years (range, 33 to 62 yr). Inclusion criteria were between 18 and 65 years in age, and hyperopia between +1.00 and +8.00 diopters (D).

Exclusion criteria were astigmatism higher than 1.50 D, systemic or ocular diseases potentially interfering with the healing process of the cornea (collagenopathies, diabetes, dry eye syndrome, anterior or posterior uveitis, etc), keratoconus and other keratic diseases (detected by videokeratography), corneal dystrophies or degeneration (including endothelial dystrophies), chronic or acute glaucoma, retinal diseases, lens opacity, history of severe ocular trauma, or previous ocular surgery. Eyes with spectacle-corrected visual acuity less than 20/100 were excluded as well. Patients who wore contact lenses were asked to discontinue use at least 15 days before preoperative videokeratography. Patients with contact lens-related corneal warpage were asked to discontinue use until corneal topography became normal and stable (the longest period was 3 months). Additionally, contact lenses were discontinued for 15 days before surgery, regardless of the topographic presence of corneal warpage.

Preoperatively, a detailed ophthalmic examination was done including spherical equivalent refraction, biomicroscopy, tonometry, and mydriatic ophthalmoscopy. Refraction was checked in normal pupillary conditions and after cycloplegia was induced with 1% cyclopentolate hydrochloride eye drops; only best subject cycloplegic refraction was considered for planning treatment and for statistical analysis (paired Student's *t*-test). Uncorrected visual acuity and spectacle-corrected visual acuity were tested at 4 meters distance using the ETDRS visual acuity charts (The Lighthouse, New York, NY), and additional lenses were held 12 mm from the corneal apex. Uncorrected visual acuity at read-

ing distance was assessed at 40 cm using the Jaeger chart. Videokeratography was done with a Keratron (Optikon 2000, Rome, Italy). During the re-epithelialization period, only anterior biomicroscopy was done. At each examination we made a full refraction measurement, as described, haze levels were detected at slit-lamp examination, and subjectively graded according to the FDA guideline protocol<sup>19</sup>, and corneal topography was assessed.

### Surgical Procedure and Postoperative Care

We used the SVS Apex Plus excimer laser (Summit Technology, Inc., Waltham, Mass) with the following operative parameters: emission wavelength 193 nm, energy fluence 180 mJ/cm<sup>2</sup>, repetition rate 10 Hz. The cut rate was assumed to be 0.25 m per pulse. The laser was calibrated for energy density before each treatment session by evaluating ablated PMMA plates and photographic gelatin.

The surgical technique was always the same. Topical anesthesia was induced using 0.4% oxybuprocaine hydrochloride eye drops. The ablation zone was marked using a 9.5 mm marking trephine centered over the pupillary entrance, and the corneal epithelium overlying the ablation zone was then removed using a disposable Desmarres blade (Janach, Como, Italy). The patient was asked to look at the green fixation light placed inside the microscope coaxially to the laser beam, while the surgeon focused the two helium-neon aiming beams on the corneal surface, over the center of the pupillary entrance.

An erodible disc with the appropriate plus prescription was inserted in the holder, and positioned in the laser rail. The laser was armed to fire using the widest diaphragm aperture only (6.5 mm), and the surgeon operated the footswitch. The number of laser pulses necessary for complete disc ablation was directly controlled by the laser system. A microphone detecting the sound of PMMA ablation was placed at the precise point where the disc was ablated; as soon as the microphone no longer detected any sound, ie, when the disc was entirely eroded, energy delivery stopped. The PMMA particles generated by ablation of the disc were aspirated by a vacuum pump placed close to the disc.

Immediately after hyperopia correction, an axicon lens was used to obtain a blend zone between the treated and untreated cornea. An axicon lens is a non-disposable optical device that delivers energy in a doughnut shape. The energy is highest at its inner rim, and progressively less toward the outer rim. Thus, the energy delivery through the axicon

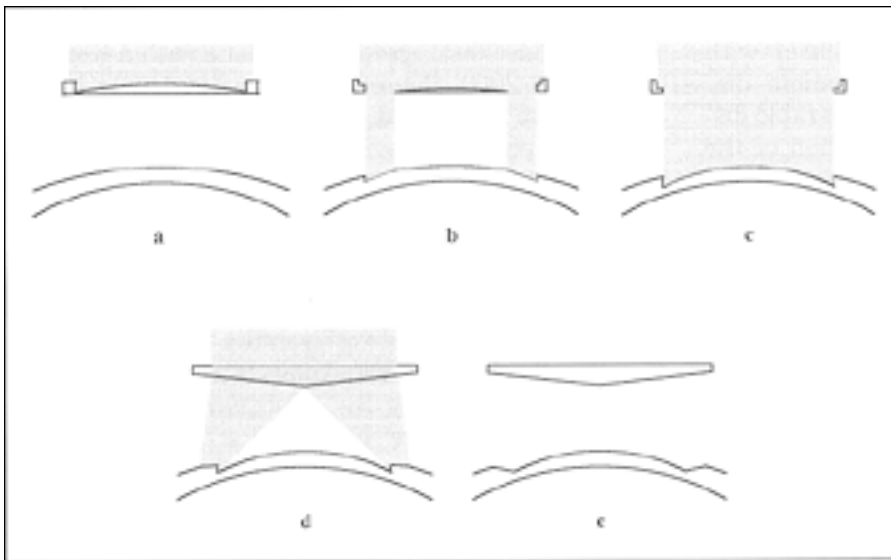


Figure 1: Sequence of the hyperopic ablation steps. (A) PMMA erodible disc interposed in the excimer beam path initially blocks the whole beam; (B) Erosion of the plano-convex disc starts at the edge, allowing an annular beam to reach and ablate the corneal stroma; (C) When the PMMA disc is fully ablated, the disc footprint is transferred onto the cornea, giving rise to an abrupt edge; (D) Insertion of an axicon lens in the beam path provides an annular beam with radially decreasing fluence; (E) After a suitable number of pulses, a linear transition is obtained outside the optical zone toward the unablated cornea.

lens resulted in a 6.5 to 9.4 mm doughnut-shaped ablation, deeper on the inside and progressively smaller toward the outer edge, where there was virtually no ablation. With the axicon lens, we entered the number of pulses established to reach an inner ablation depth intended to match the peripheral ablation depth obtained by the disc, as indicated by the manufacturer. This number of pulses was related to each disc's dioptric power. A schematic drawing of the ablation sequence is shown in Figure 1.

All eyes received the same postoperative therapy: mydriatic drops (cyclopentolate hydrochloride) at the end of the treatment, antibiotic drops (netilmicin sodium) and non-steroidal anti-inflammatory drops (diclofenac sodium) 4 times daily until re-epithelialization. Patients were instructed to take pain-relief tablets (meclofenamate sodium every 8 hours). No bandage contact lenses were used, but a pressure patch was applied for 24 hours. Once re-epithelialization occurred, all eyes were treated with corticosteroid drops: fluorometholone sodium was given 4 times daily for the first postoperative month, 3 times daily for the second month, and then twice and once per day for 15 days each. The corticosteroid dose was not titrated.

## RESULTS

All 25 eyes were examined until re-epithelialization occurred, and then at 1, 3, 6, and 12 months after surgery. A smaller series of 11 eyes was followed-up for 24 months.

Mean preoperative spherical equivalent refraction ( $-SD$ ) for the 25 eyes was  $+3.86 - 1.46$  D (range,  $+1.50$  to  $+6.25$  D). Mean attempted correction was  $+3.38 - 0.97$  D (range,  $+1.00$  to  $+4.00$  D). Preoperatively, 4 eyes (16%) had uncorrected visual

acuity of 20/40 or better and the remaining 21 eyes (84%) were between 20/200 and 20/50. Two eyes (8%) had uncorrected visual acuity at reading distance of J1, two (8%) at J4, three (12%) had J6, and the remaining 18 eyes (72%) had J8. Fifteen eyes (60%) had preoperative spectacle-corrected visual acuity of 20/20 or better, seven (28%) had spectacle-corrected visual acuity of 20/25 to 20/32, and three eyes were 20/40 to 20/80. We aimed for a final refraction within  $-0.50$  D of emmetropia in 16 eyes (64%), and between  $+1.00$  and  $+2.25$  D in the other 9 eyes, where the goal of the treatment was either to reduce hyperopia higher than  $+4.00$  D (highest feasible correction), or to balance the contralateral eye.

Re-epithelialization occurred in all eyes by the fifth postoperative day, despite the large de-epithelialization diameter, and no eye had any epithelial defect thereafter.

## Spherical Equivalent Refractive Outcome

Figure 2 summarizes the refractive results (mean and standard deviation) during follow-up. Figure 3 shows the difference between attempted and achieved correction 1 month after surgery (spherical equivalent); all eyes showed a greater myopic shift for higher attempted corrections. The overcorrection progressively reduced over time so that at 6 months after surgery there were 11 eyes (44%) within  $-0.50$  D and 16 (64%) within  $-1.00$  D of intended correction; at 12 months (Fig 4) the eyes within  $-0.50$  D were again 11 (44%) and those within  $-1.00$  D were 19 (76%). At each follow-up examination, the difference in refractive outcome was always statistically significant when compared to the previous examination (3 mo  $P = .015$ ; 6 mo  $P = .00014$ ; 12 mo  $P = .044$ ). For a smaller series of 11 eyes with 24

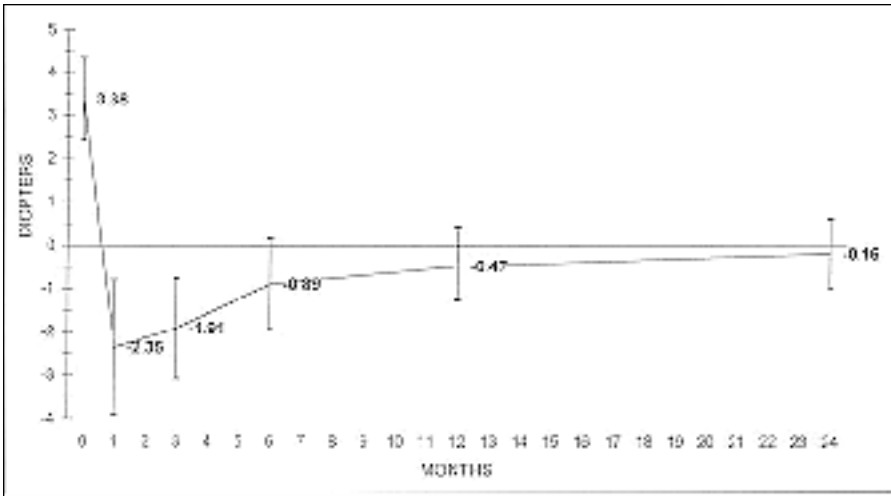


Figure 2: Time-course of spherical equivalent refractive error during follow-up (mean and standard deviation).

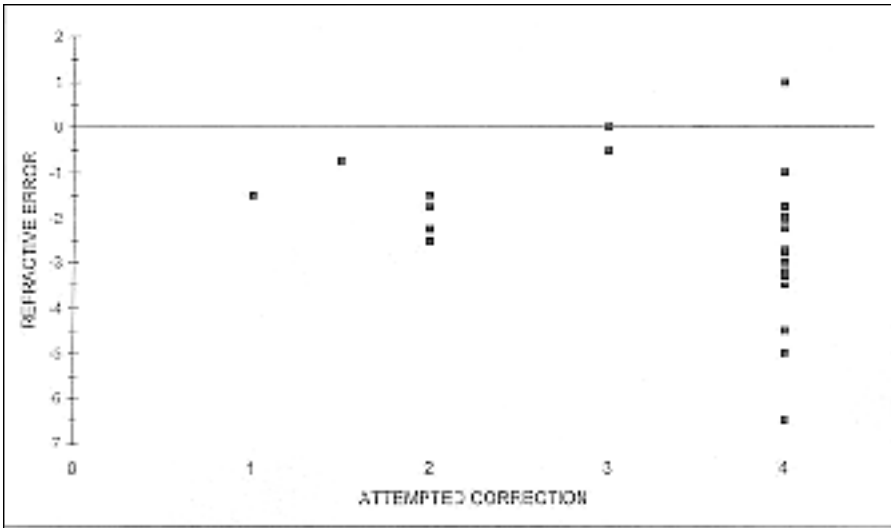


Figure 3: Spherical equivalent refractive error at 1 month as the difference between attempted and achieved correction, in relation to the attempted correction (X-axis).

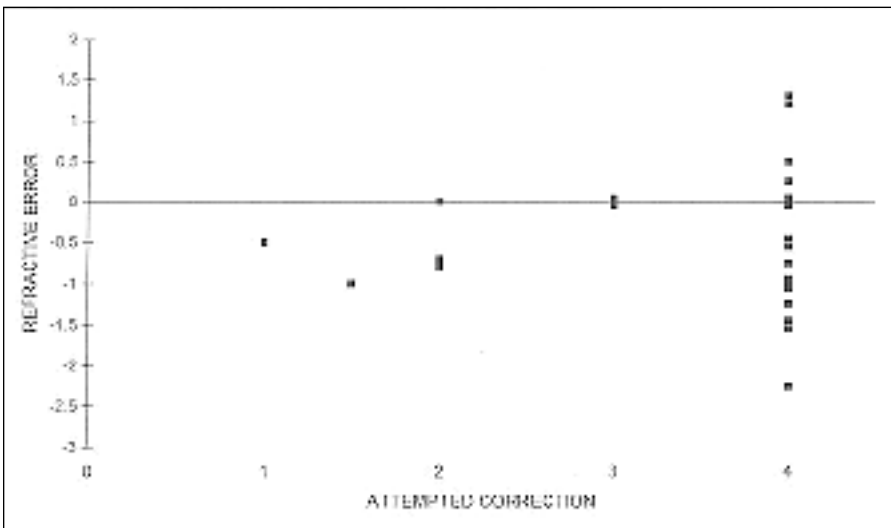


Figure 4: Spherical equivalent refractive error at 12 months as the difference between attempted and achieved correction, in relation to the attempted correction (X-axis).

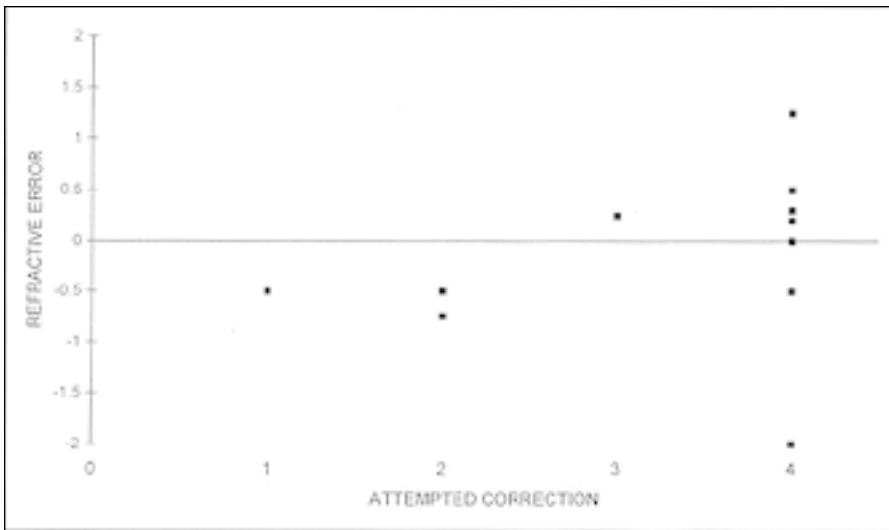


Figure 5: Spherical equivalent refractive error at 24 months as the difference between attempted and achieved correction, in relation to the attempted correction (X-axis).

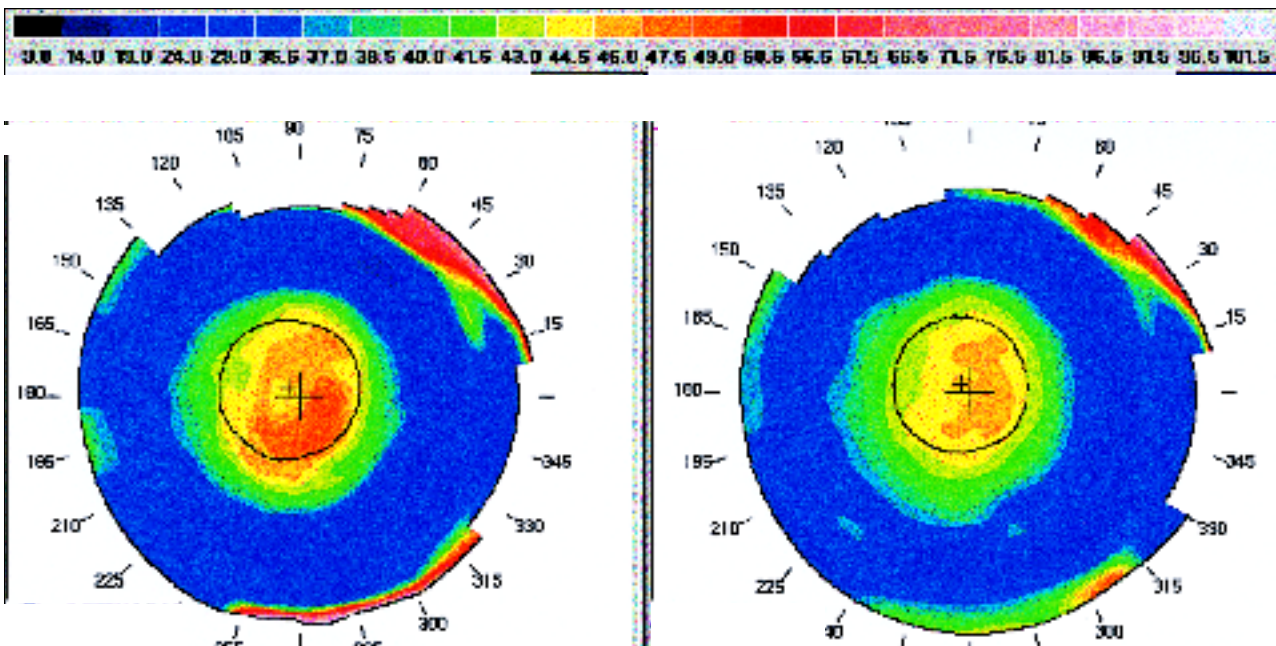


Figure 6: Corneal topography after treatment. **Left** a hyperopic correction 1 month after treatment. Note the irregularity in the area overlying the pupillary entrance. **Right** the same eye 1 year after surgery. The pattern is more regular, but the effective optical zone is small, despite the 6.5 mm intended ablation diameter.

months follow-up, 8 eyes (72.7%) were within  $-0.50$  D and 9 eyes (81.8%) were within  $-1.00$  D of the intended correction (Fig 5). The difference in refractive outcome between 12 and 24 months was not statistically significant ( $P = .11$ ).

#### Refractive Cylinder Modifications

Although not statistically significant, the procedure induced some change in refractive astigmatism that was irregular during the first postoperative months, but became more regular in pattern over time (Fig 6). One month after PRK, the mean change in refractive astigmatism was  $+0.53 - 1.00$  D

( $P = .21$ ), with a range of  $+2.50$  to  $-1.50$  D (the minus sign indicating a reduction in astigmatism, and the plus sign an increase). Six months after PRK, the mean change in astigmatism was  $+0.75 - 0.67$  D (range, 0 to  $+2.00$  D,  $P = .09$ ). At 12 months, the mean change in astigmatism was  $+0.46 - 0.63$  D (range,  $+1.50$  to  $-0.75$  D,  $P = .32$ ), and 24 months after treatment it was  $+0.61 - 0.69$  D (range,  $+1.75$  to  $-0.50$  D,  $P = .44$ ).

#### Uncorrected Distance Visual Acuity

Due to the initial overcorrection, 1 month after surgery uncorrected visual acuity was improved in

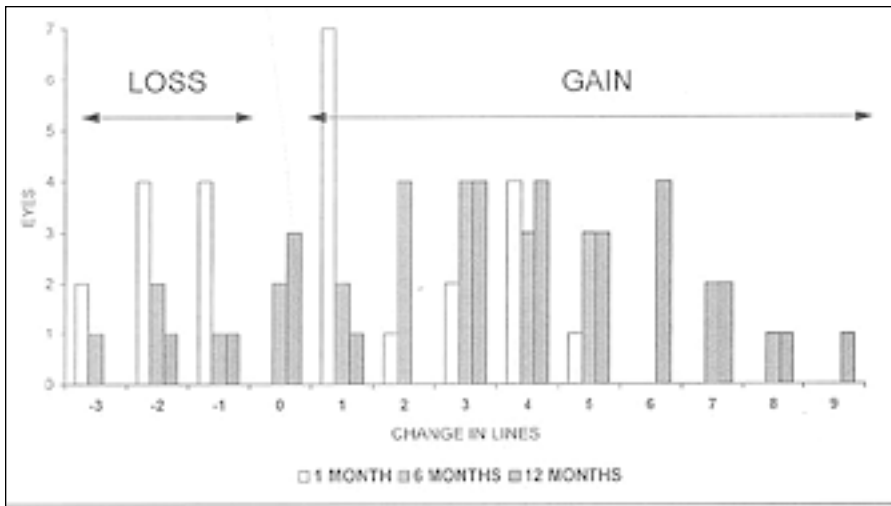


Figure 7: Uncorrected distance visual acuity changes (Snellen values) at 1, 6, and 12 months. Each bar represents the number of eyes having lost (negative values) or gained (positive values) visual acuity lines without spectacles in comparison to preoperative values.

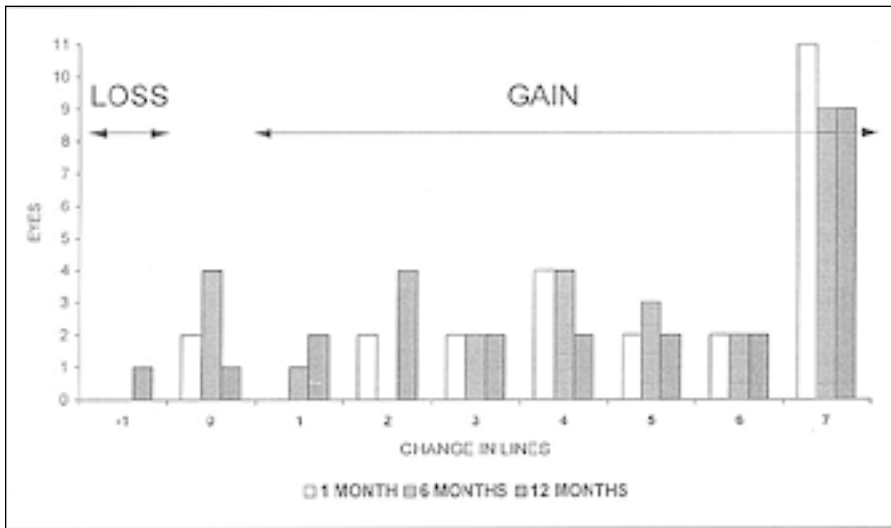


Figure 8: Uncorrected visual acuity at reading distance changes (Snellen values) at 1, 6, and 12 months. Each bar represents the number of eyes having lost (negative values) or gained (positive values) visual acuity lines without spectacles in comparison to preoperative values.

15 eyes (60%), of which 6 (24%) showed an improvement of 4 to 5 lines. However, 10 eyes (40%) lost 1 to 3 lines. Six months after PRK, 19 eyes (76%) had improved uncorrected visual acuity, and 13 eyes (52%) gained 3 to 8 lines. Only four eyes (16%) lost uncorrected visual acuity (1 to 3 lines). Twelve months after surgery, 20 eyes (80%) had improvement in uncorrected visual acuity compared to preoperative values; 19 eyes (76%) gained 3 to 9 lines (Fig 7). Two eyes (8%) still showed some worsening (1 to 3 lines). Two years after treatment, all eyes showed an improvement compared to preoperative values, which ranged between 3 and 8 lines in 9 eyes (81.8%).

**Uncorrected Visual Acuity at Reading Distance**

At the first postoperative month, uncorrected visual acuity at reading distance had improved in 23 eyes (92%) due to the myopic overshoot; this improvement was remarkable (5 to 7 lines) in 15 of these eyes (60%). Two eyes showed no change com-

pared to preoperative values. Six months after surgery, we found the same outcome as at 1 month. At 12 months, uncorrected visual acuity at reading distance was again improved in 23 eyes (92%, 1 to 7 lines), unchanged (1 eye) and worsened (1 eye, 1 line) (Fig 8). Two years after surgery, uncorrected visual acuity at reading distance was improved in 9 eyes (81.8%), and unchanged in the remaining 2 eyes.

**Spectacle-Corrected Visual Acuity**

One month after surgery, 8 eyes (32%) had lost 2 or more lines compared to preoperative values, 12 eyes (48%) had lost 1 line, and the remaining 5 eyes (20%) were unchanged. Six months after treatment, there were still 3 eyes (12%) with a 2-line loss, and 7 eyes (28%) with a loss of 1 line. Twelve eyes remained unchanged (48%) and 3 eyes gained 1 line (12%). At 12 months, 6 eyes (24%) showed a spectacle-corrected visual acuity loss of 1 line, 15 eyes (60%) were unchanged, and 4 eyes (16%) gained 1

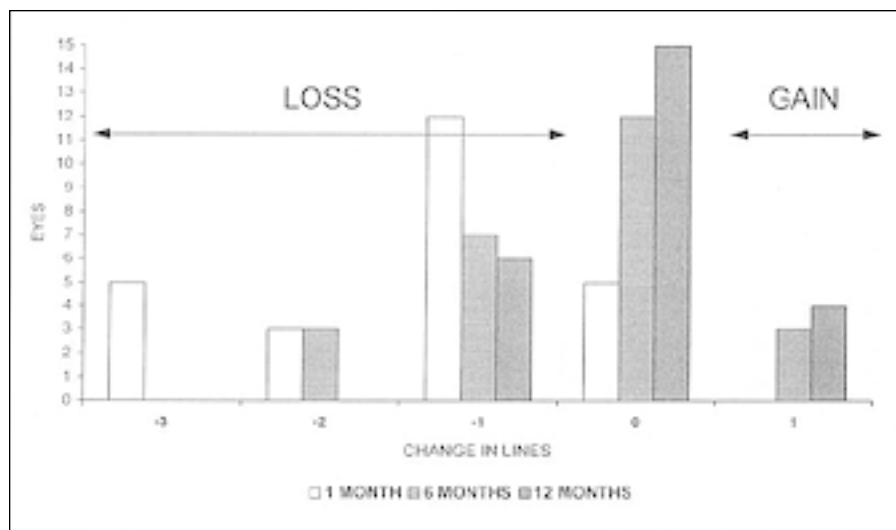


Figure 9: Spectacle-corrected visual acuity changes (Snellen values) at 1, 6, and 12 months. Each bar represents the number of eyes having lost (negative values) or gained (positive values) visual acuity lines using spectacle-corrected visual acuity, in comparison to preoperative values.

line (Fig 9). Two years after treatment, 3 eyes (27.3%) still revealed a loss of 1 line, 7 eyes (63.6%) were unchanged, and 1 eye (9.1%) gained 1 line.

#### Haze

All eyes showed some corneal haze during follow-up, but the deeper ablation in the mid-periphery meant the haze was circular and did not involve the optical part of the cornea. One month after surgery, 21 eyes (84%) had no haze and 4 eyes (16%) had grade 1. At 6 months, 9 eyes (36%) had no haze, 10 eyes (40%) had haze of grade 1, and 6 eyes (24%) had haze of grade 2. Twelve months after treatment, 4 eyes (16%) had no haze, 15 eyes (60%) had haze of grade 1, and 6 eyes (24%) had haze of grade 2. At 24 months, 2 eyes (18.2%) had no haze, and the remaining 9 eyes (81.8%) had grade 1 haze.

#### DISCUSSION

The correction of myopia and myopic astigmatism with the excimer laser has proved accurate, safe and predictable, but the correction of hyperopia remains a challenge. Only a few papers have reported results<sup>15,21-24</sup>, and consolidated results are still needed. Different ablation strategies may produce central corneal steepening to correct hyperopia and peripheral flattening to blend the steepening. Among them, the small-beam flying-spot scanning ablation looks interesting for its flexibility and the large ablation diameter achievable, but also broad-beam excimer lasers may reach the same target, either by masking the central cornea with rotating opaque masks<sup>15,21,23</sup>, or by delivering energy peripherally in a rotating fashion.

This paper presented the results of a broad-beam excimer laser which uses the erodible disc technique combined with the axicon lens. This procedure was

effective in reducing hyperopia, although its predictability needs to be assessed for larger numbers.

Particularly interesting is the large myopic shift at the 1-month examination. This was greater for higher corrections, (+4.00 D), where results were scattered over a 7.50 D range (Fig 2). A small overcorrection during the early postoperative period is also one of the features of myopic PRK, where the amount of hyperopic shift is primarily related to the amount of attempted correction (the higher, the larger) and, secondarily, to the ablation diameter (the smaller, the larger).<sup>4</sup> The initial overcorrection after hyperopic PRK in our series was greater than after standard myopic PRK for a similar range of corrections (-1.00 to -4.00 D).<sup>4</sup> This is probably because of the small effective optical zone generated by the treatment (Fig 5), regardless of the nominal large ablation diameter (6.5 mm optical part plus a 3.0 mm blend zone). The overcorrection decreased with time so that at 12 months, mean refractive error was close to the mean attempted correction (Fig 1). However, looking at the standard deviation of spherical refractive outcome (Fig 2), it was high at 1 month after treatment and followed a trend toward constant reduction during follow-up. Nevertheless, it remained quite high for a small range of attempted correction even long after treatment.

The large myopic overshoot during the early postoperative period influenced the uncorrected visual acuity and the uncorrected visual acuity at reading distance so that the greatest advantage for patients during the first months after surgery was the gain in reading ability without eyeglasses (most of the patients were presbyopes), whereas the uncorrected visual acuity gain was satisfactory only at 6 months after surgery.

A second question is the refractive stability of the procedure. This report refers to a 24-month follow-up for a limited series of eyes, so we cannot assess whether refraction was stable at this stage. The statistical analysis of all 25 eyes, though limited in value because of the small number of eyes evaluated, showed a statistically significant change in refraction at each postoperative examination up to 12 months. For the smaller series of 11 eyes, there was no significant change between 12 and 24 months after treatment. All this implies that one of the greatest concerns of these results is the long time to refractive stabilization, which implies a long time to visual recovery.

Another concern is the loss of spectacle-corrected visual acuity lines, especially during the immediate postoperative period. This was mainly due to the corneal irregularity (Fig 6) generated by the treatment and did tend to regress with time, though at 12 months after treatment, 6 eyes still had a loss of 1 Snellen line. This loss was never related to corneal haze, which was confined to the peripheral cornea in all eyes. Regarding this last issue, haze rates were higher than in a standard reference series of eyes treated by myopic PRK for a similar range of corrections.<sup>4</sup> This would imply a greater stromal reaction, which justifies the large changes in refraction during our follow-up. But, besides the stromal reaction, we believe epithelial changes play an important role both in smoothing the central irregularity and determining refractive regression.

#### REFERENCES

1. Brancato R, Carones F. Indications, results, and complications of refractive corneal surgery with lasers. *Curr Opin Ophthalmol* 1994;5:90-97.
2. Campos M, Nielsen S, Szerenyi K, Garbus JJ, McDonnell PJ. Clinical follow-up of phototherapeutic keratectomy for treatment of corneal opacities. *Am J Ophthalmol* 1993;115:433-440.
3. Brancato R, Scialdone A, Carones F, Bertuzzi A. Excimer laser ablation of a corneal protuberance. *J Cataract Refract Surg* 1992;18:111-112.
4. Brancato R, Tavola A, Carones F, Scialdone A, Gallus G, Garancini P, Fontanella G. Excimer laser photorefractive keratectomy for myopia: results in 1165 eyes. *Refract Corneal Surg* 1993;9:95-104.
5. Salz JJ, Maguen E, Nesburn AB, Warren C, Macy JI, Hofbauer JD, Papaioannou T, Berlin M. A two-year experience with excimer laser photorefractive keratectomy for myopia. *Ophthalmology* 1993;100:873-882.
6. Maguen E, Salz JJ, Nesburn AB, Warren C, Macy JI, Papaioannou T, Hofbauer JD, Berlin MS. Results of excimer laser photorefractive keratectomy for the correction of myopia. *Ophthalmology* 1994;101:1548-1557.
7. Tengroth B, Epstein D, Fagerholm P, Hamberg-Nystrom E, Epstein D. Excimer laser photorefractive keratectomy for myopia. Clinical results in sighted eyes. *Ophthalmology* 1993;100:739-745.
8. Piebenga LW, Matta CS, Deitz MR, Tauber J, Irvine JW, Sabates FN. Excimer laser photorefractive keratectomy for myopia. *Ophthalmology* 1993;100:1335-1345.
9. Carson CA, Taylor HR. Excimer laser treatment for high and extreme myopia. *Arch Ophthalmol*. 1995;113:431-436.
10. Marshall J, Trokel S, Rothery S, Krueger RR. Photoablative reprofiling of the cornea using an excimer laser: photorefractive keratectomy. *Lasers in Ophthalmol* 1986;1:21-48.
11. Seiler T, McDonnell PJ. Excimer laser photorefractive keratectomy. *Surv Ophthalmol* 1995;40:89-118.
12. Carones F, Brancato R, Morico A, Venturi E, Gobbi PG. Compound myopic astigmatism correction using a mask in-the-rail excimer laser delivery system. *Eur J Ophthalmol* 1996;6:221-233.
13. Forster W, Beck R, Borrmann A, Busse H. Correcting myopic astigmatism with an areal 193 nm excimer laser ablation. *J Cataract Refract Surg* 1995;21:278-281.
14. Snibson GR, Carson CA, Aldred GF, Taylor HR. One-year evaluation of excimer laser photorefractive keratectomy for myopia and myopic astigmatism. Melbourne Excimer Laser Group. *Arch Ophthalmol* 1995;113:994-1000.
15. Dausch D, Klein R, Schröder E. Excimer laser photorefractive keratectomy for hyperopia. *Refract Corneal Surg* 1993;9:20-28.
16. Maloney RK, Friedman M, Harmon T, Hayward M, Hagen K, Gailitis RP, Waring GO III. A prototype erodible mask delivery system for the excimer laser. *Ophthalmology* 1993;100:542-549.
17. Brancato R, Carones F, Trabucchi G, Scialdone A, Tavola A. The erodible mask in photorefractive keratectomy for myopia and astigmatism. *Refract Corneal Surg* 1993;9(suppl.):S125-S130.
18. Gobbi PG, Carones F, Scagliotti F, Venturi E, Brancato R. A simplified method to perform excimer laser photorefractive keratectomy using the erodible mask technique. *Refract Corneal Surg* 1994;10(suppl.):S246-S249.
19. Brancato R, Carones F, Morico A, Gobbi PG. Photorefractive keratectomy for compound myopic astigmatism with an eye cup erodible mask delivery system. *J Refract Surg* 1996;12:501-510.
20. Office of Device Evaluation, Division of Ophthalmic Devices, Food and Drug Administration. Draft clinical guidance for the preparation and contents of an investigational device exemption (IDE) application for excimer laser devices used in ophthalmic surgery for myopic photorefractive keratectomy (PRK). *Refract Corneal Surg* 1991;6:265-270.
21. Dausch D, Klein R, Landes M, Schröder E. Photorefractive keratectomy to correct astigmatism with myopia or hyperopia. *J Cataract Refract Surg* 1994;20(suppl.):252-257.
22. Danjoux J-P, Kalski RS, Cohen P, Lawless MA, Rogers C. Excimer laser photorefractive keratectomy for hyperopia. *J Refract Surg* 1997;13:349-355.
23. Pietilä J, Mäkinen P, Pajari S, Uusitalo H. Photorefractive keratectomy for hyperopia. *J Refract Surg* 1997;13:504-510.
24. Brancato R, Carones F, Morico A, Venturi L, Vigo L, Spinelli A, Gobbi PG. Hyperopia correction using an erodible mask excimer laser delivery system coupled to an axicon: preliminary results. *Eur J Ophthalmol* 1997;7:203-210.